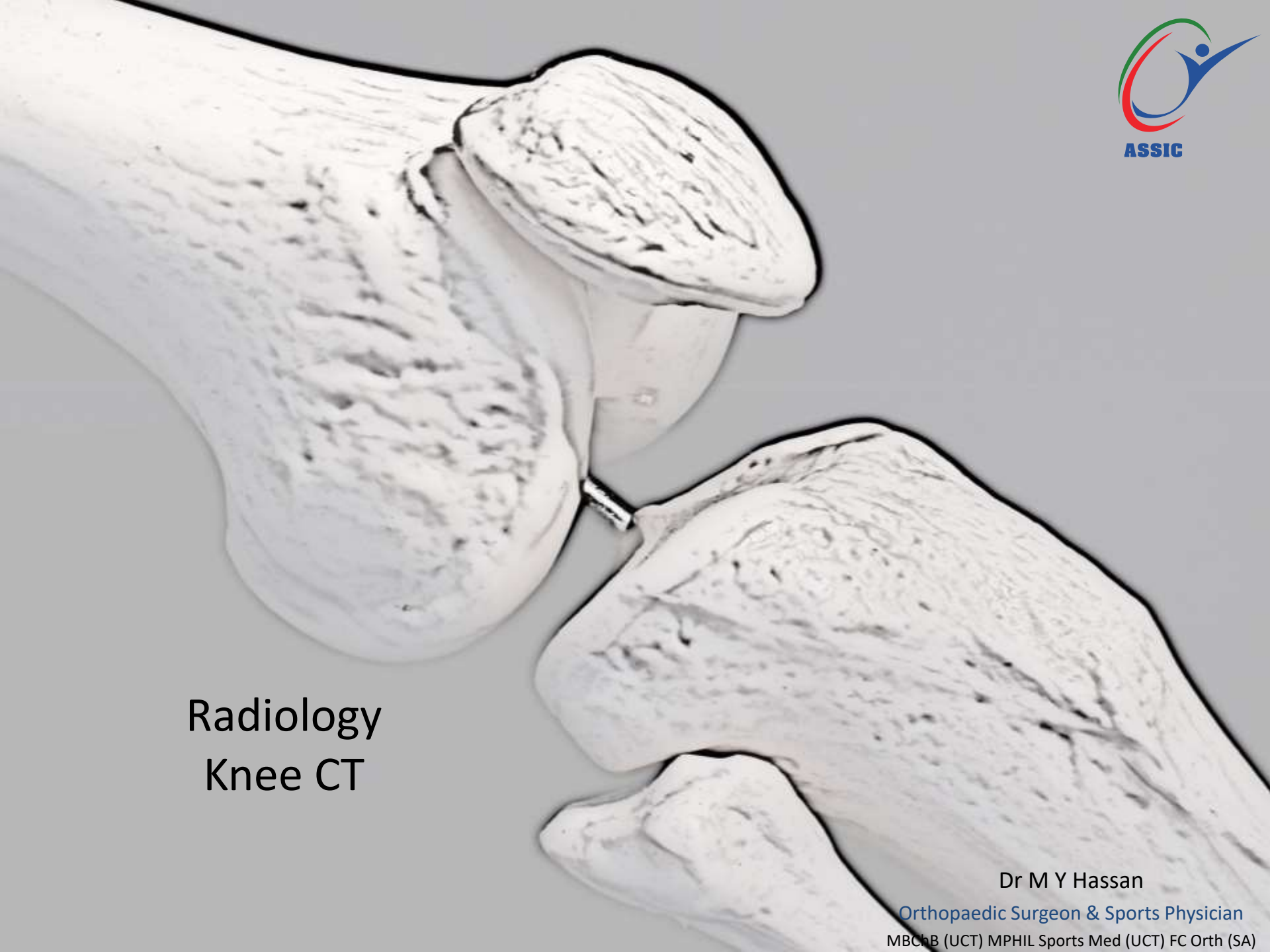

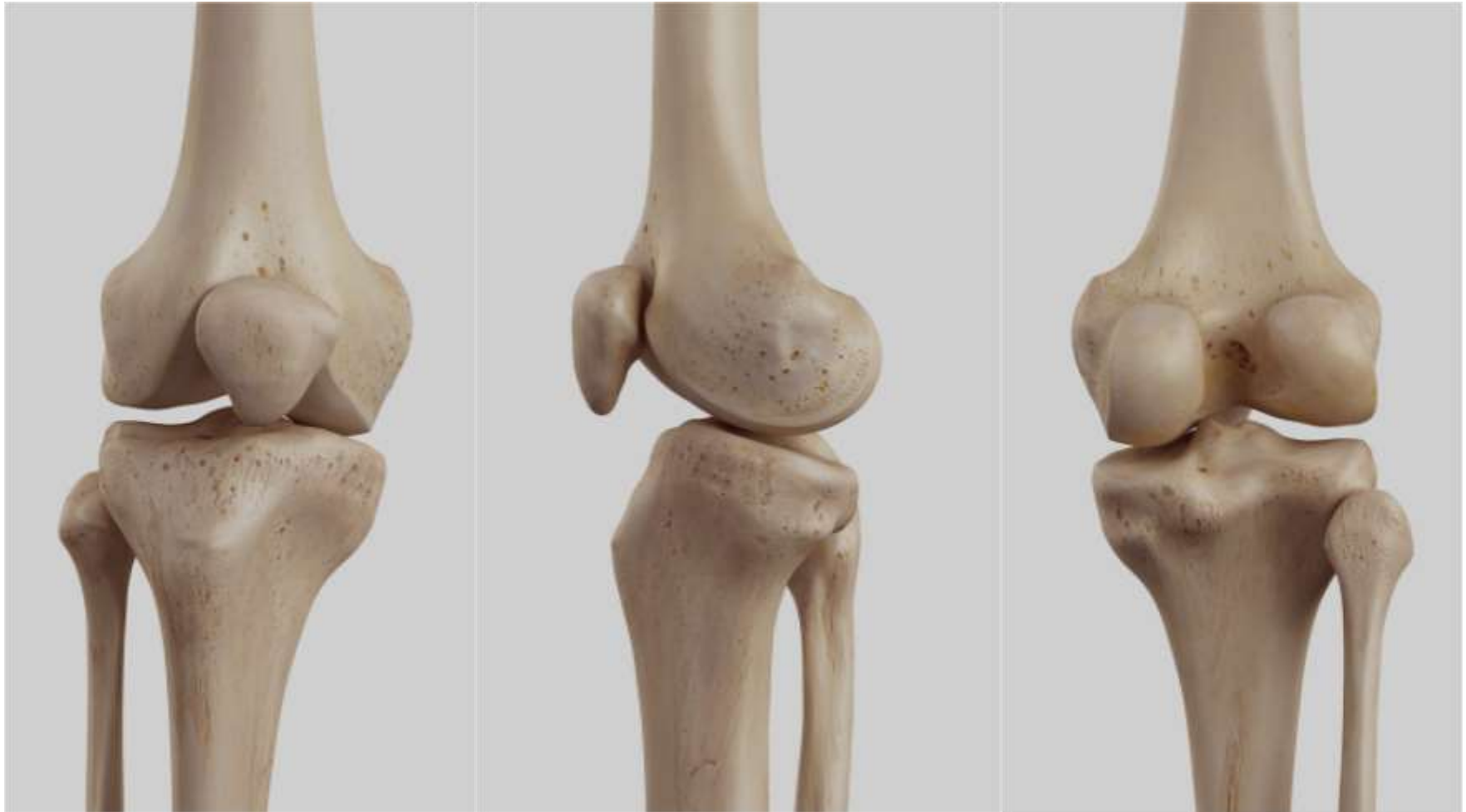Radiology  
Knee CT

Dr M Y Hassan

Orthopaedic Surgeon & Sports Physician  
MBChB (UCT) MPHIL Sports Med (UCT) FC Orth (SA)

## Normal Bone Anatomy of the Right Knee



Anterior view of right knee

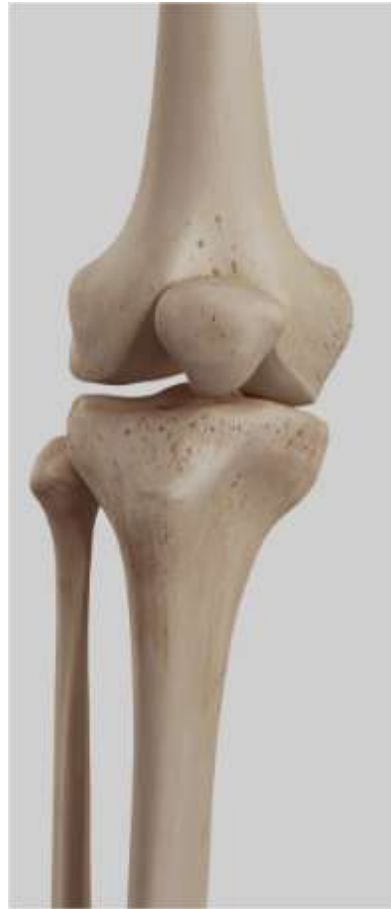Medial view of right knee

Posterior view of right knee

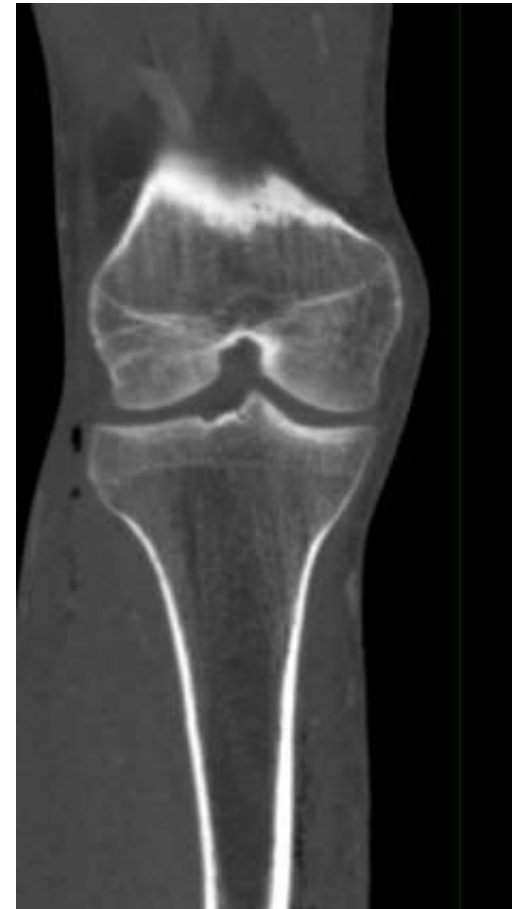## CT Knee



Standing right knee

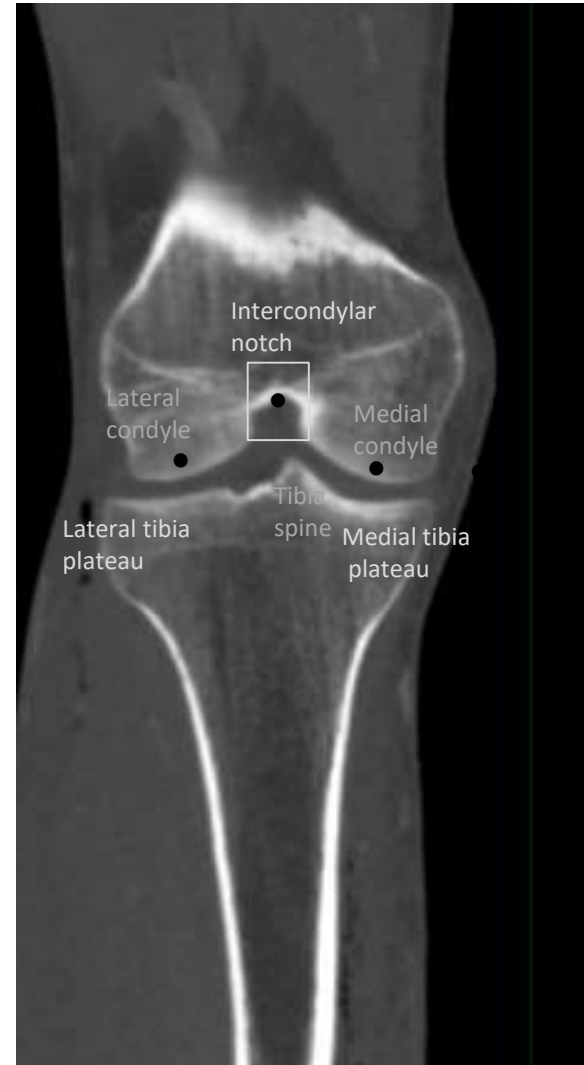
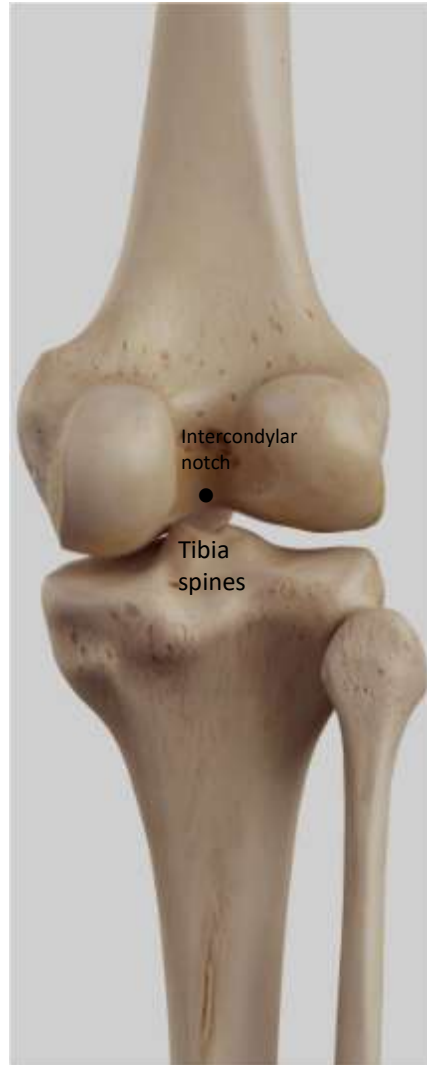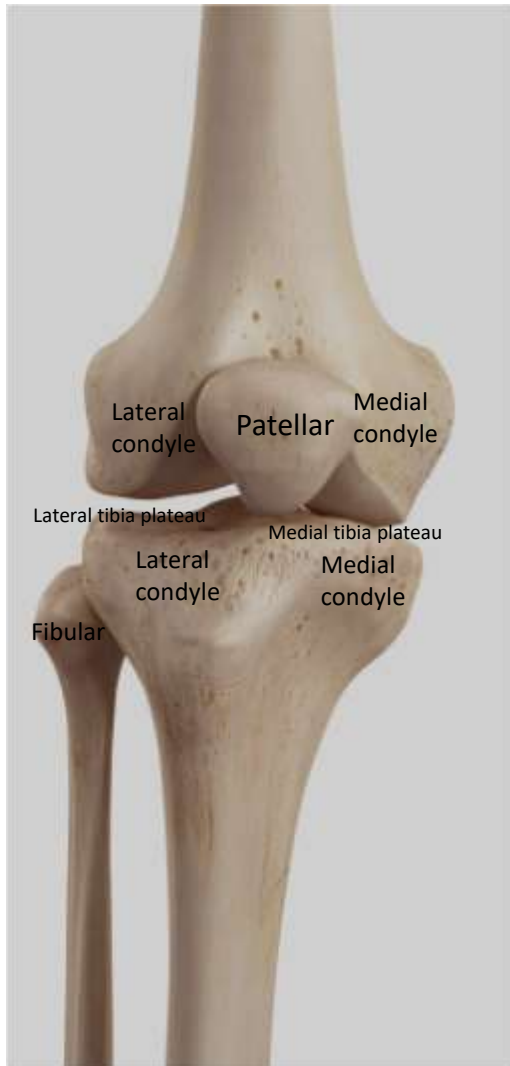


Bone anatomy of right knee



Coronal CT view of right knee

# CT scan right knee

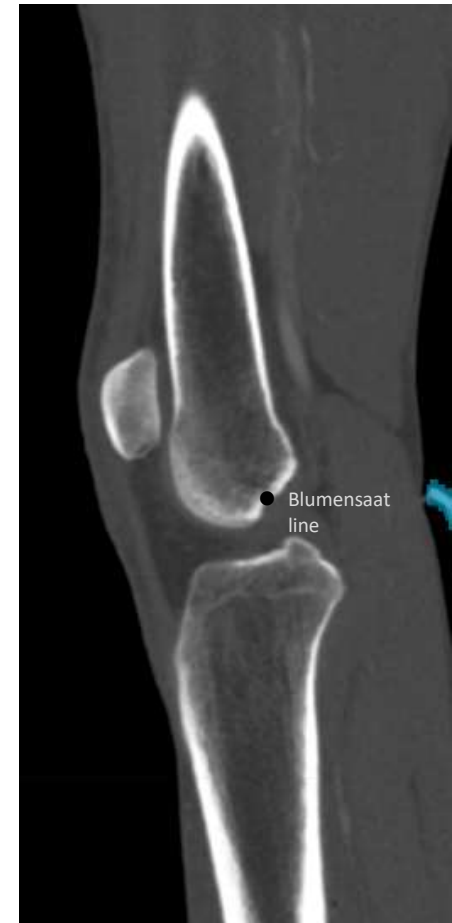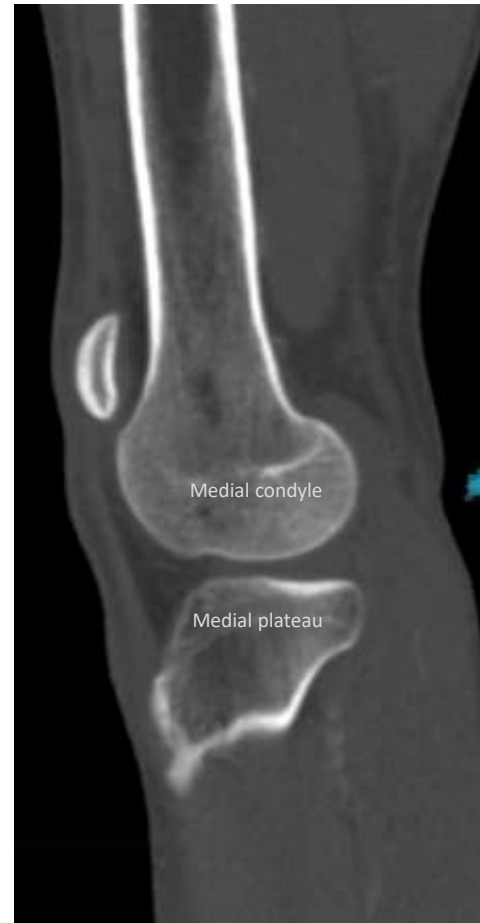

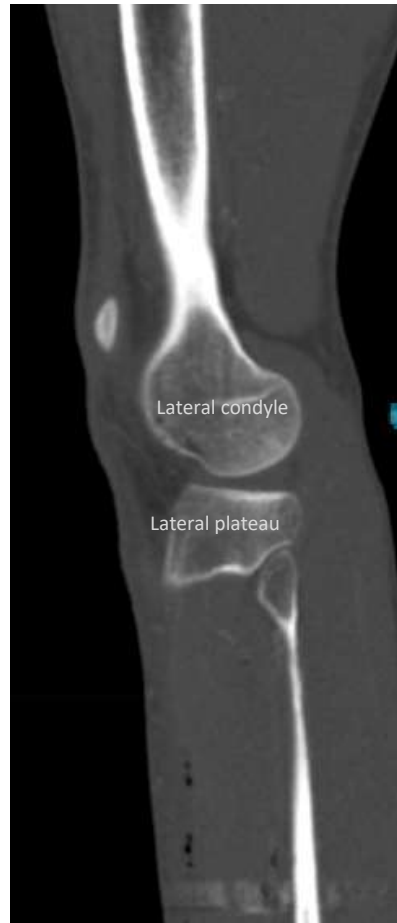
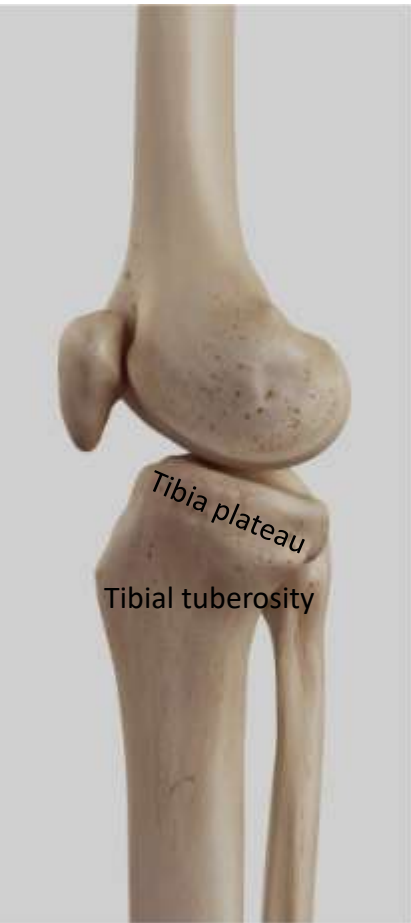Anterior view of right knee

Posterior view of right knee

Coronal CT view of right knee

# CT Knee Sagittal View



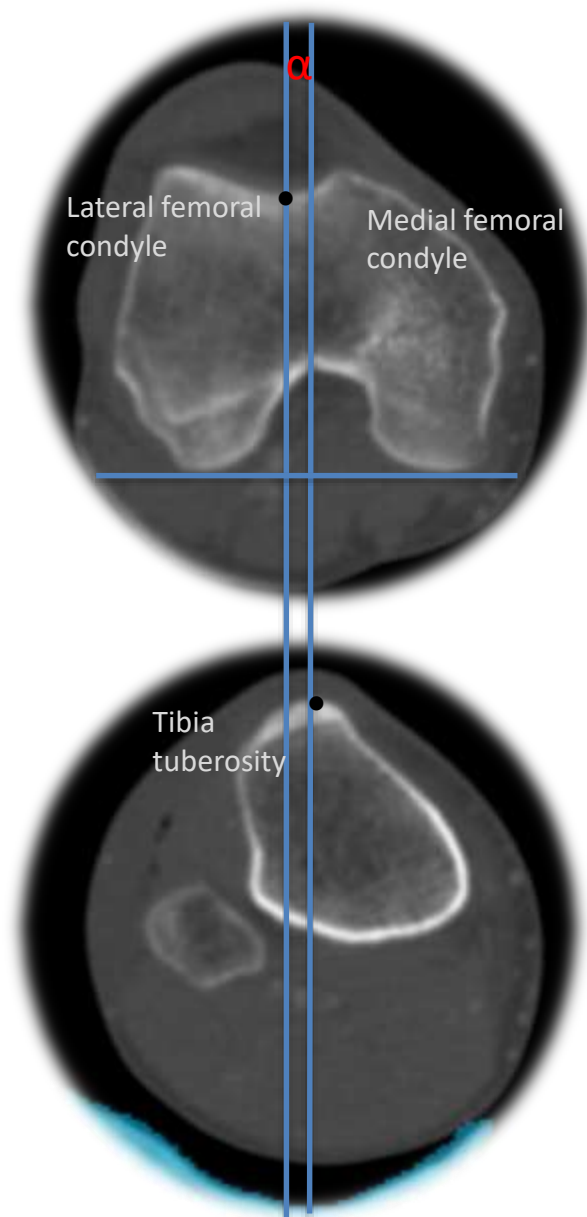
Bone anatomy

Sagittal lateral

Sagittal medial

Mid Sagittal

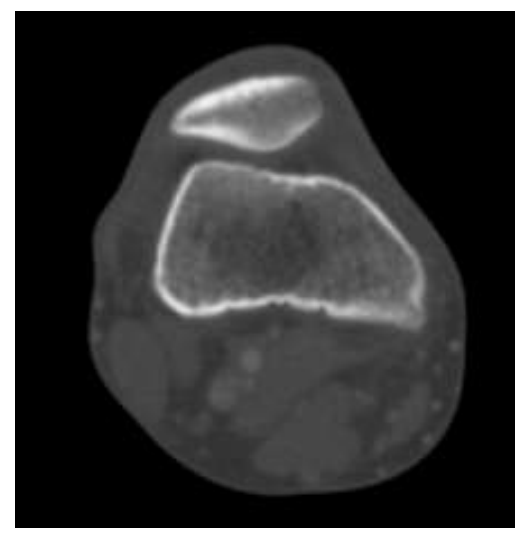
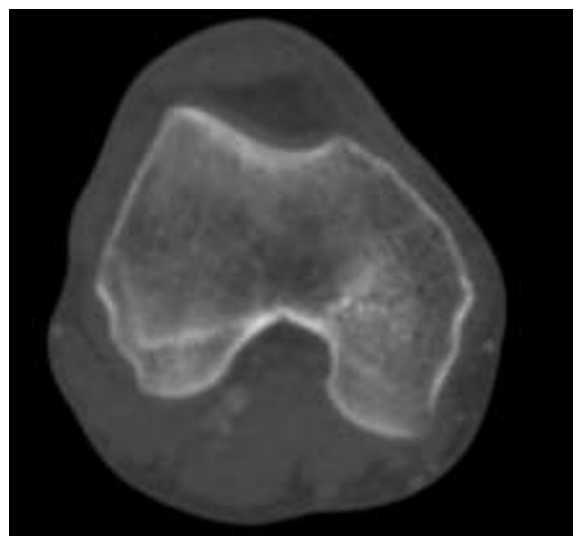
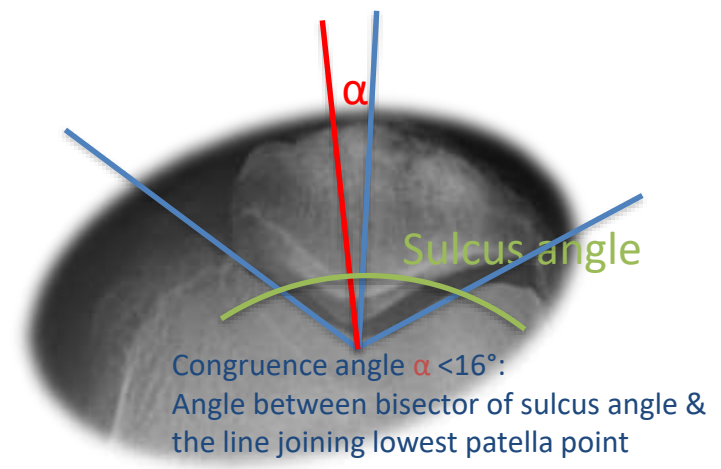
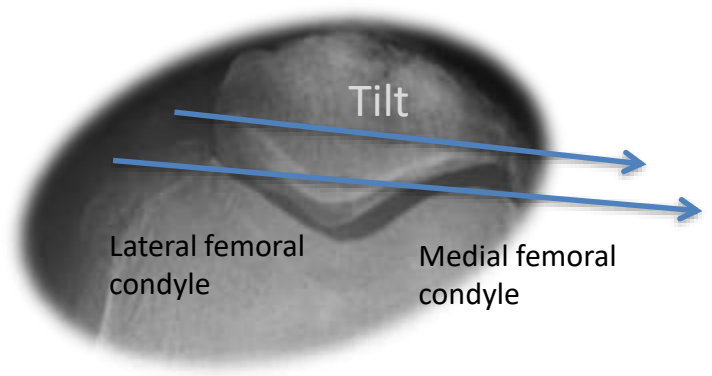
## Patellar position using CT scan

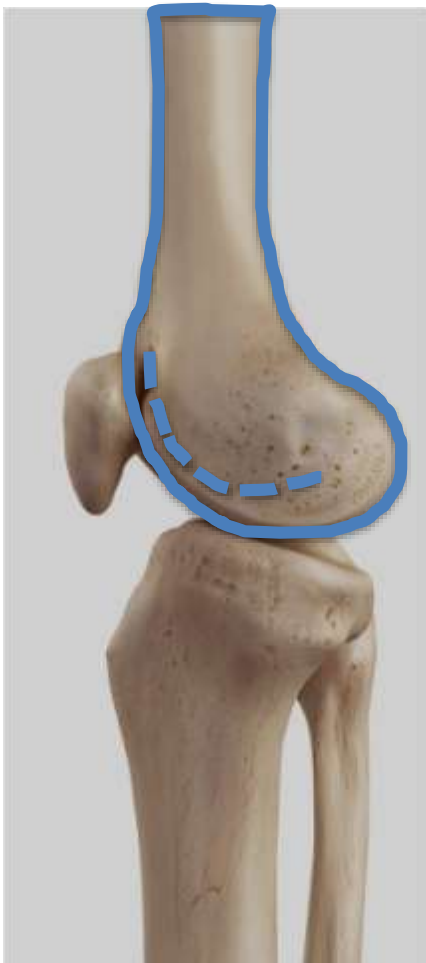

$\alpha$  Tibial tubercle-to-trochlear groove (TT-TG) distance

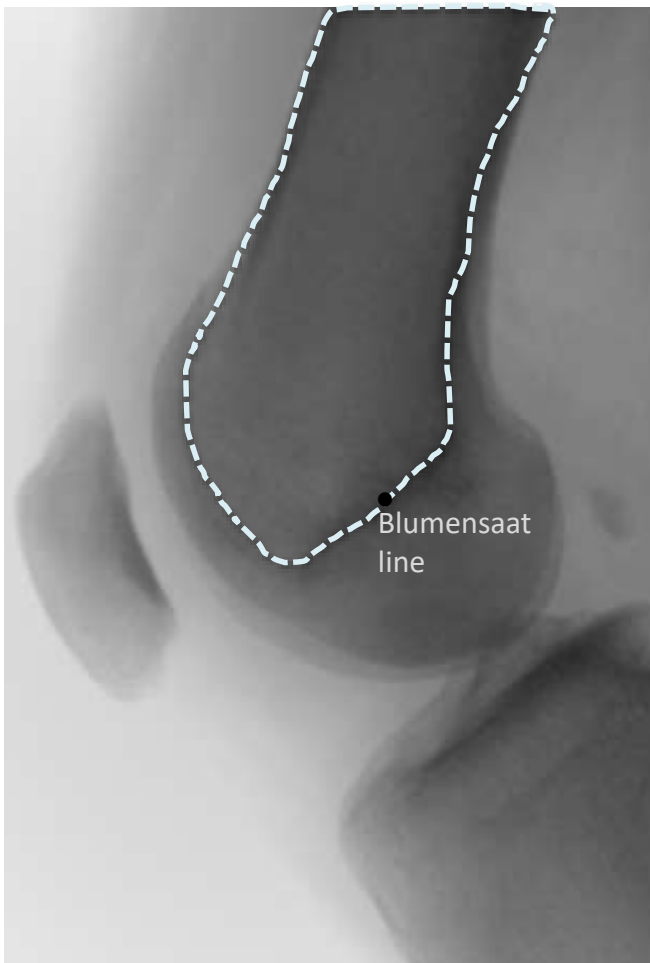
Superimposed images used to calculate TT-TG.

# Patellar position

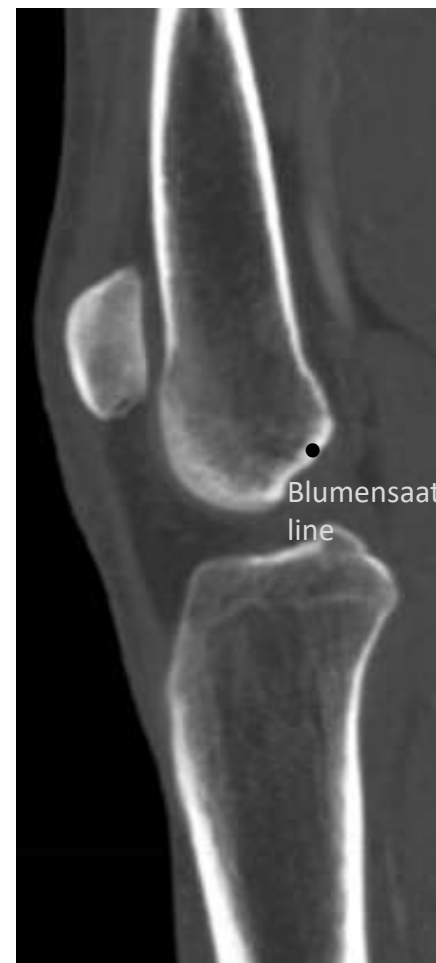



Bone anatomy



Lateral knee X-ray



CT: Mid Sagittal

Blumensaat  
line